

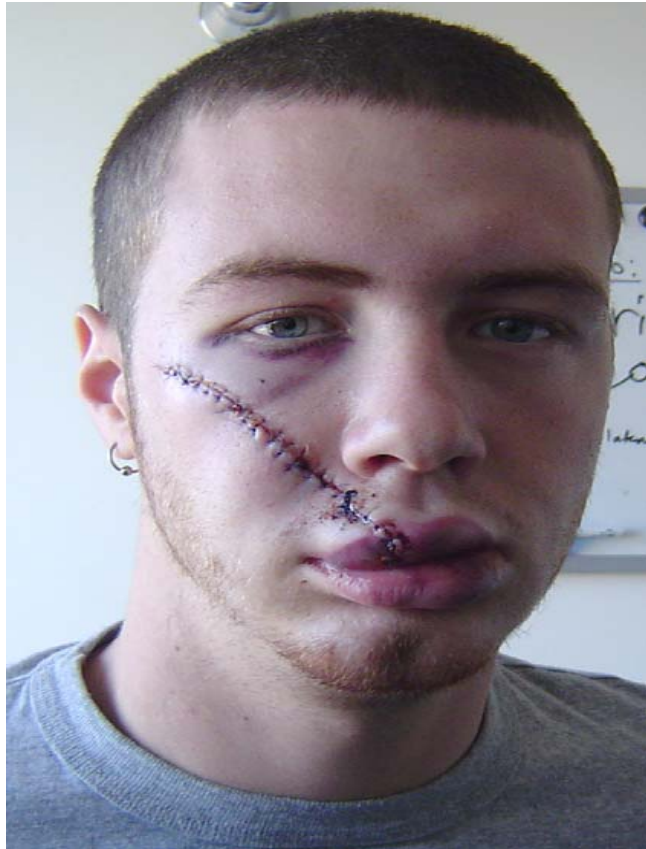

**CASE STUDY – University of Illinois, Chicago Student**

**By: Philip Narini, MD, FACS, Chief of Plastic Surgery at Lakeridge Health**


Shown below are photos of a 24 year old college student that sustained this laceration during an assault with a knife. The wound was through-and-through the upper lip and cheek. It was sutured and repaired primarily in the emergency department.

This case demonstrates the effective results after treat of an acute facial laceration with NewGel+™.



***Fig1- October 27, 2007 (Before using NewGel+™)***

“Approximately 2 weeks after the lip repair, he was treated with NewGel+™ which he used 12 hours per day seven days per week”.



***Fig 2- February 15<sup>th</sup>, 2008 (After 12 weeks using NewGel+™)***

“The pictures taken at 12 weeks post injury show a dramatic result with no perceptible scar across the lip or vermillion border. Only a small portion of the scar in the upper third of his face is minimally visible”.